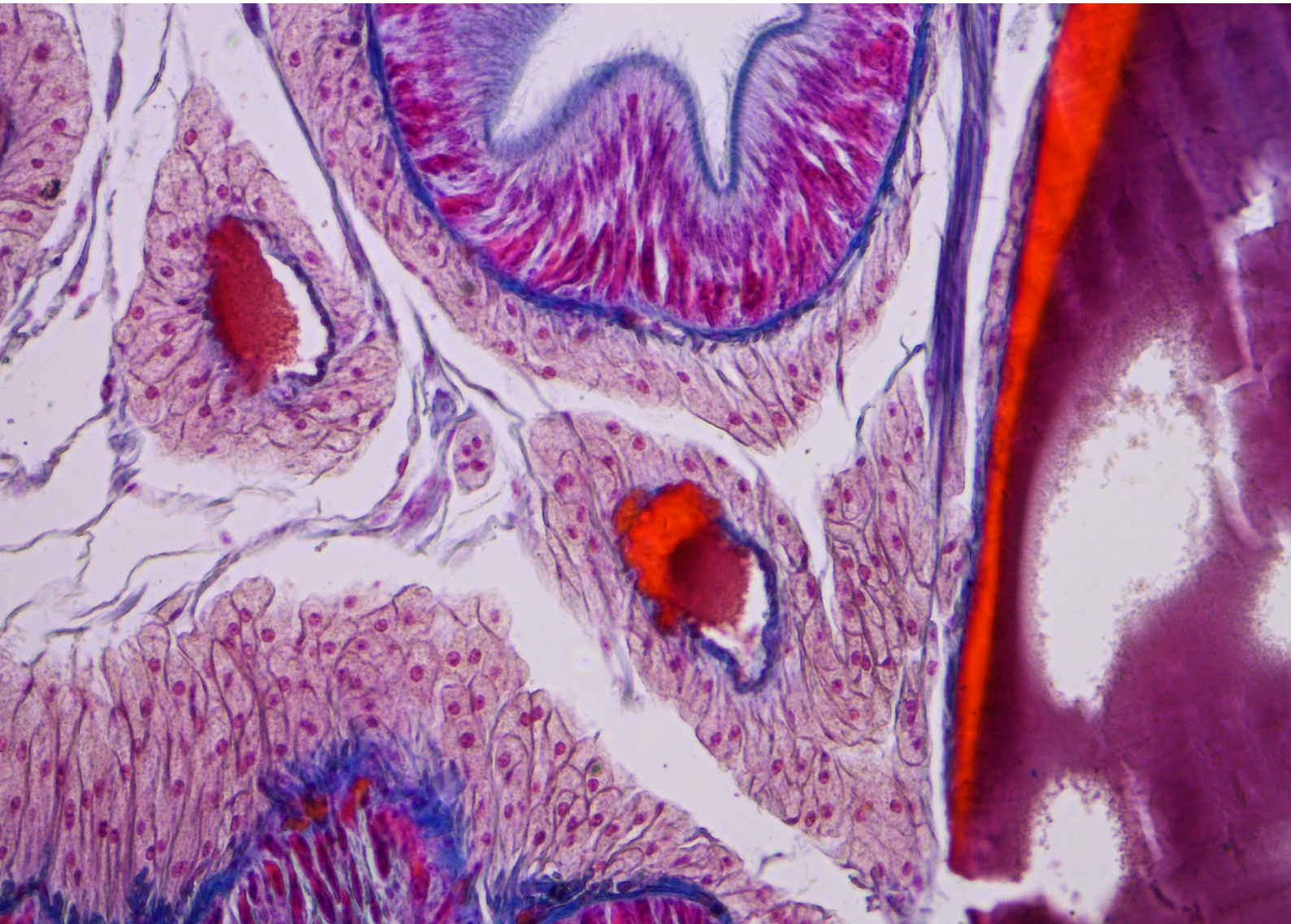

Microscopic Anatomy in the Study of Medicine: Fundamentals of Histology



Seeing beyond

Microscopic Anatomy in the Study of Medicine: Fundamentals of Histology

Author: Dr. Silvia Zenner-Gellrich
Carl Zeiss Microscopy GmbH, Germany

Date: February 2020

The term histology refers to the study of the microscopic structure of tissues and organs. Histology is a central subject in university degree courses dedicated to human, dental, and molecular medicine. The aim is to acquire detailed knowledge of the structure, form, and function of cells, tissues, and organs. This fundamental knowledge is important for the reliable detection of disease-related changes in day-to-day clinical practice and in drawing conclusions regarding the potential causes of diseases and ways of treating them.

“Microscopic anatomy is an important component of anatomical training for every medical specialty. Without understanding the fundamentals of histology, many conditions and findings cannot be properly understood or classified. Histology is also indispensable in biomedical research: from stem-cell to cancer research, modern histological methods are being used and are vital to our understanding of these areas. I seek to impart this fundamental knowledge to prospective doctors and scientists. A further objective is to provide them with comprehensive knowledge concerning methods and diagnostics. During the course, we place special emphasis on training students’ individual observation skills by sketching slides and practicing diagnostic processes. At the end of the course, each student should be able to sketch a histological slide, identify it based on its visual characteristics, and justify a diagnosis. This is part of the final examination as well,” explains Prof. Britsch, Director of the Institute of Molecular and Cellular Anatomy at Ulm University in Germany (1).

Introduction

The histology course that forms part of studies toward a medical degree covers fundamental principles and knowledge that will subsequently be important in the students’ day-to-day clinical practice. Students examine various slides with a microscope and identify them, study their characteristics, and internalize what they have learned by sketching the results. As diseases cause characteristic changes to tissues, cells, and organs, they can only be detected and accurately classified if the structure, form, and functionality of the healthy tissue are known. Taking into account the known symptoms and comparing healthy and diseased tissue provides an indication of the potential causes of the disease.

Hands-On Procedure

Light microscopes (Figure 1) are typically used during hands-on student training. Light microscopy permits the examination of cells (cell biology), healthy tissues (histology), and pathological changes in tissue (histopathology).

An introduction to microscope functionality is required to make hands-on work with a microscope as effective as possible. The device in use is also adjusted to the current user so they can work comfortably with the microscope.

Students in histology courses examine a wide range of slides (Figure 2).

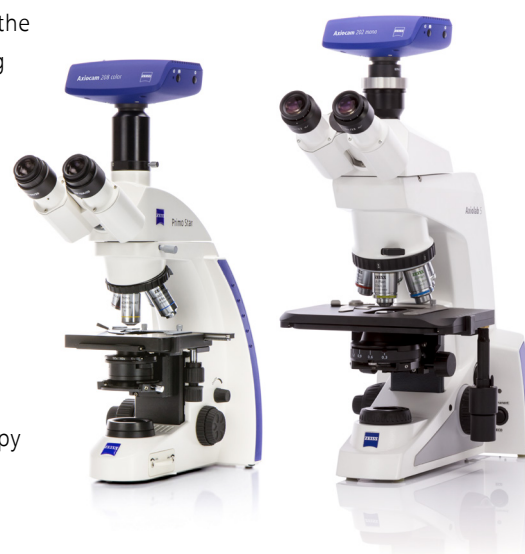

Figure 1
ZEISS Primo Star and ZEISS Axiolab 5 light microscopes

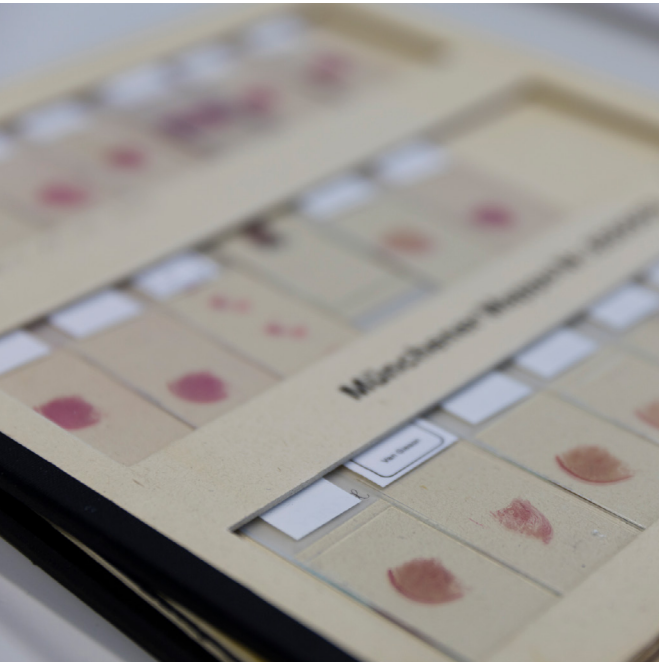

Figure 2 Microscopic analyses in histology courses primarily focus on fixed slides

These slides consist of a selection that is relevant to students' subsequent working lives as medical professionals. For example, they use microscopes to analyze connective and supporting tissue as well as muscle, nerve, and epithelial tissue (Figure 3, 4).

Course slides are stored in slide cases. The slides primarily consist of thin sections that are fixed, stained, and

embedded in paraffin. Ground sections of bone, blood smears, or fixed sputum may be additionally used. Universities typically have their own selection of slides, which are made available to students in slide cases.

A similar approach is often used in hands-on student training. The slide is initially examined with the naked eye. This makes it possible to detect staining

and major structures and to identify the regions that are to be examined in detail under the microscope.

The slide is then placed on the microscope stage with the cover glass on top for analysis. First, the lowest magnification is used to examine the slide. Once the microscope image is focused to suit the individual's visual acuity, the slide is displayed at the largest overview using

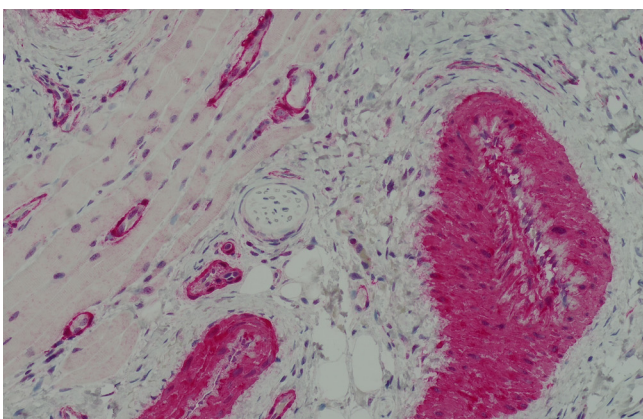


Figure 3 Skin muscle tissue, HE staining, courtesy of Dr. Gisela Metzler, Universitäts-Hautklinik Tübingen, Germany

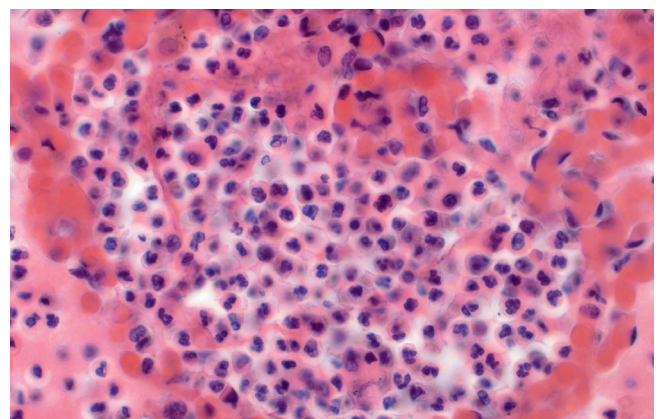


Figure 4 Lung tissue, HE staining

a 4× or 5× objective. This overview image provides an initial impression of the entire slide, its type and structure, its staining, and its boundaries (2).

Analyses are subsequently carried out with additional 10× or 40× objectives, and may be performed at maximum magnification so that the smallest details and those characteristic of the sample can be made visible.

Students should answer a wide range of questions:

- What is the sample in question?
- Are any characteristic areas visible?
- Are they able to detect any pathogenic changes, and if so, which ones?

Staining Techniques

Histological staining is used when the aim is to make tissue structures visible. A wide range of dyes are available. The dye binds to defined tissue structures (3). A distinction is made between routine and special dyes. Routine histological dyes are used, among other things, to make tissue complexes, tissue reactions, and deposits in tissues visible. Hematoxylin-eosin (HE) is a standard dye that interacts directly with tissue and cell components. Collagen fibers and cellular and intercellular components are stained

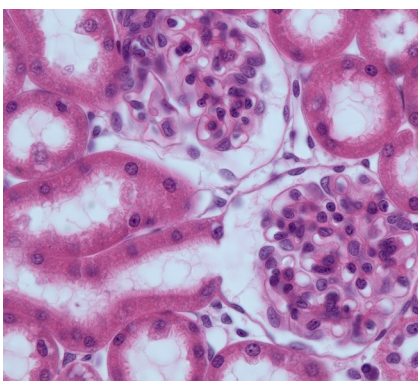


Figure 5 Renal tissue of a rat, HE staining Nuclei appear purple, cell plasma pink



Figure 6 The technique of sketching by hand helps students consolidate and remember what they have learned. Microscope images are sketched in schools and universities

red; cell nuclei, ribosomes, and the endoplasmic reticulum are stained blue-purple (Figure 5).

Hand Drawings

Hand drawings of the microscope image are often created to make the students' observations of the key structural elements more precise and to help them internalize what they have seen (Figure 6). Creating a thorough, accurate sketch makes it possible to determine in detail how the tissue is structured and to define the characteristics that distinguish it. It also makes the proportions and relationships to neighboring tissue visible. If Papanheim-stained blood smears are copied, for example, it is important to depict the precise proportions of erythrocytes, leucocytes, and thrombocytes and to observe both how frequently they occur and their spatial distribution in the blood. Leucocytes can be identified by

a cell nucleus, while the round, slightly concave erythrocytes do not contain a nucleus.

The drawing must be clearly labeled. It should describe the slide and staining depicted, the magnification at which the analysis was carried out, and any particularly relevant details.

In addition to hands-on practice and direct work with the microscope, slides can be digitized and made available to students online or offline. This allows students to access the digitized slides anywhere and at any time.

Summary

In the course of medical training, microscopic anatomy prepares students for their subsequent working lives as medical professionals or researchers.

The aim is to acquire knowledge of characteristic structures so that structural changes in tissues, cells, and organs can be used to draw conclusions regarding functional changes and their impacts on human health.

Working with a microscope during the histology course allows students to practically study a tissue section by magnifying the overview image to include the smallest tissue details. Viewing the fine details of the tissue's structure establishes a basis for a successful learning and motivates students.

A range of ZEISS microscopes can be used to support successful learning and teaching during histology courses. Available products include classic classroom microscopes as well as scanners for digitizing slides.

Recommended Products

Teaching microscopes by ZEISS, especially those from the Primo Star range. Various packages are available featuring either versions with preset Köhler illumination (fixed Köhler 415500-0051-000) or versions on which the Köhler illumination can be adjusted (415500-0056-000). In addition to these, a package with a 100× dry objective is also available (415500-0053-000).

Digital classrooms can be set up using Wi-Fi-enabled cameras and microscopes (415500-0059-000). The ZEISS Labscope app gives instructors an overview of all networked microscopes on their iPad, and they can follow the progress of their students' work online. Students can also annotate their images. Among other features, the optional Labscope Teacher module allows lecture notes or other teaching materials to be sent to all networked devices.

The author would like to thank Prof. Britsch for his kind support in preparing this application note.

References

- [1] https://www.uni-ulm.de/fileadmin/website_uni_ulm/med.inst.090/Bilder/Presse/Der_Histokurs_in_Ulm_-_Mein_Studienort_-_Via_medici.pdf; excerpt from December 13, 2019
- [2] <https://anatomie.med.uni-rostock.de/fileadmin/Institute/anatomie/Lehre/Histokurs/histoscript.pdf>; excerpt from December 13, 2019
- [3] Mulisch, M. and Welsch, U. (ed.): Romeis Mikroskopische Technik; 18th edition. Spektrum Akademischer Verlag, Heidelberg 2010. p. 181.



Carl Zeiss Microscopy GmbH

07745 Jena, Germany

microscopy@zeiss.com

www.zeiss.com/education